

ENT SURVIVAL GUIDE

CONTENTS

NOSE	3
EPISTAXIS -----	3
Figure 1: Pack Insertion: NB elevation of nasal tip + angle of insertion -----	4
Figure 2: The fully inserted pack: NB nil protruding anteriorly-----	5
NASAL FRACTURE -----	6
PERIORBITAL CELLULITIS / MIDFACIAL INFECTION -----	6
THROAT	7
TONSILLITIS -----	7
QUINSY -----	7
Figure 3: View of the Tonsils (Normal): The X marks the usual site of aspiration in a quinsy-----	8
Figure 4: Grey Venflon needle & Syringe: Note flange – Do not insert beyond incisors-----	9
ACUTE DYSPHAGIA = FOOD BOLUS / FOREIGN BODY OBSTRUCTION: -----	9
TONSILLAR HAEMORRHAGE -----	10
FISH BONE / ODYNOPHAGIA (PAINFUL SWALLOW) -----	10
NECK STABBING -----	11
STRIDOR / UPPER AIRWAY OBSTRUCTION -----	12
NECK ABSCESS -----	12
EAR	13
OTITIS MEDIA -----	13
OTITIS EXTERNA -----	13
ACUTE PERFORATED TYMPANIC MEMBRANE -----	13
ACUTE MASTOIDITIS -----	14
BELL’S PALSY -----	14
PINNA LACERATION -----	14

NB: SHADED AREAS ARE REALLY MEANT FOR ENT JUNIORS RATHER THAN FY2 OR ED JUNIORS UNLESS EXPERIENCED IN PROCEDURE

NOSE

EPISTAXIS “A little bit of blood goes a long way a lot of blood can hide.”

This is the commonest ENT emergency. Be aware of which patients are likely to give problems:

- The elderly (tends to be more posterior, more co-morbidities)
- Those on anti-coagulation therapy (e.g. aspirin, clopidogrel, warfarin, NOACs)
- Those with recent nasal trauma (due to disruption of the anterior ethmoidal artery)

Treatment:

- Instigate 1st aid management:
 - Suction clot (using small yankuer sucker)
 - Spray inside of nose with co-phenylcaine (lignocaine 5% + phenylephrine 0.5%)
 - Pinch the soft part of the nose – sealing the front of the nose so no blood escapes
 - Maintain pinch for 15 mins without stopping
 - Ice pack to back of neck / forehead
 - If blood running posteriorly into mouth tip head forward and spit into bowl
- Inspect nose with headlight + thudicum’s speculum and look for bleeding point
 - (Little’s area is the commonest site – this is found on the anterior septum)
 - Remember to check oropharynx for active bleeding (gargle water if clot present)
- If bleeding point seen cauterise with AgNO₃ stick: **(DO NOT TRY IF INR >2.0)**
 - Apply local pressure using cotton bud soaked in co-phenylcaine for 1 min
 - Dry area with cotton bud then apply tip of AgNO₃ stick to point & press for 3-5 secs
 - Cauterise area circumferentially around bleeding point
 - Then cauterise bleeding point
- If successful observe for 30 mins & discharge with Naseptin / Vaseline for 2 weeks
- Advise-No blowing/picking nose/exertion/straining/hot drinks, Sneeze with mouth open

If still bleeding despite cautery or bleeding point not seen:

- Obtain IV access – send FBC + Group & Save (COAG + U&E if indicated)
- Insert 8-10cm merocel nasal tampon / rapid rhino: (See Figure 1 & 2)
 - Suction clot (using small yankuer sucker) & spray with co-phenylcaine
 - Lift tip of nose with thumb of left hand
 - Lubricate merocell with aqueous jelly
 - Fully insert tampon with thumb of right hand – fast & hard (it is painful)
 - (Aim along floor of nose i.e. level with the external auditory meatus)
 - Instil Normal saline if merocell / air if Rapid Rhino
- If bleeding stopped (N.B. check oropharynx) refer to on call ENT at QEUH:
 - IVI (Keep NBM)
 - Kardex (omit anticoagulant therapy) + ECG if cardiopath
 - (Augmentin 375mg TDS if prosthetic heart valves)

If still bleeding despite packing: Contact ENT ON CALL

Figure 1: **Pack Insertion:** NB Elevation of nasal tip + Angle of insertion

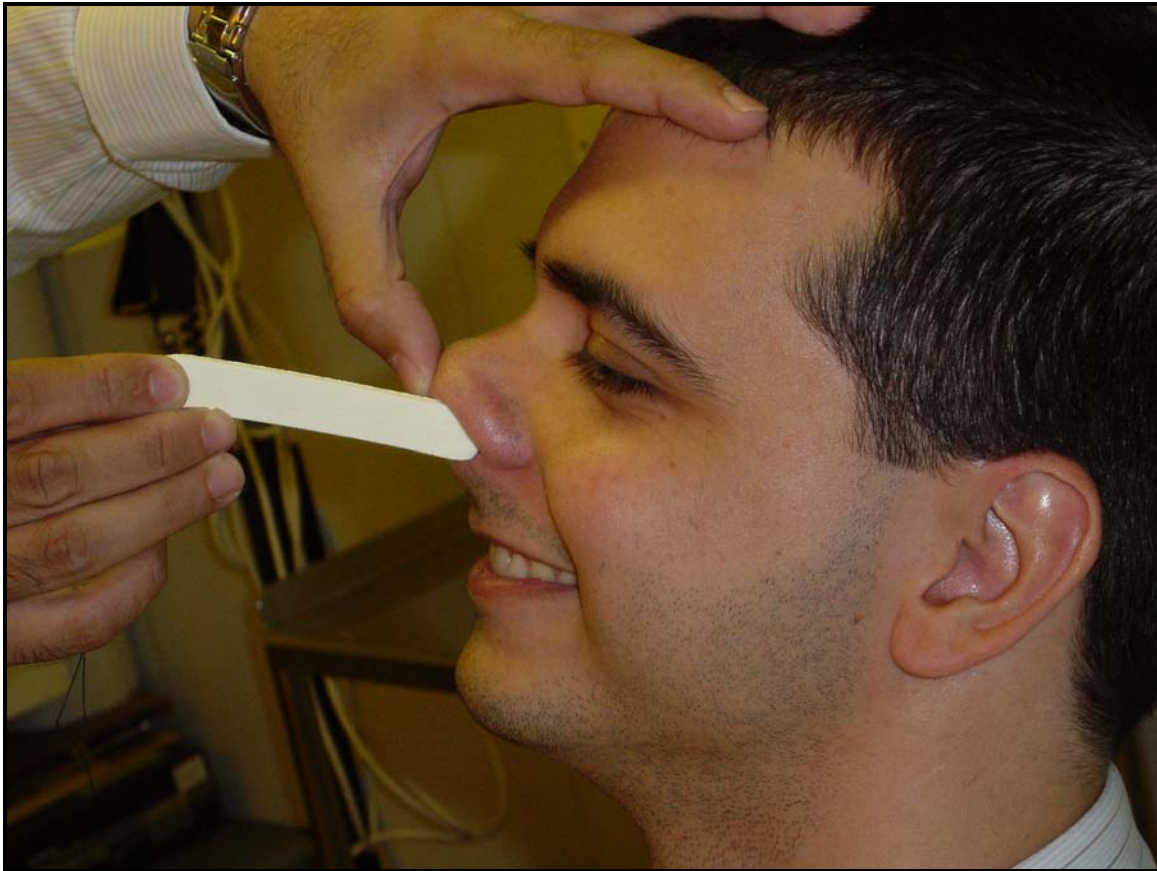
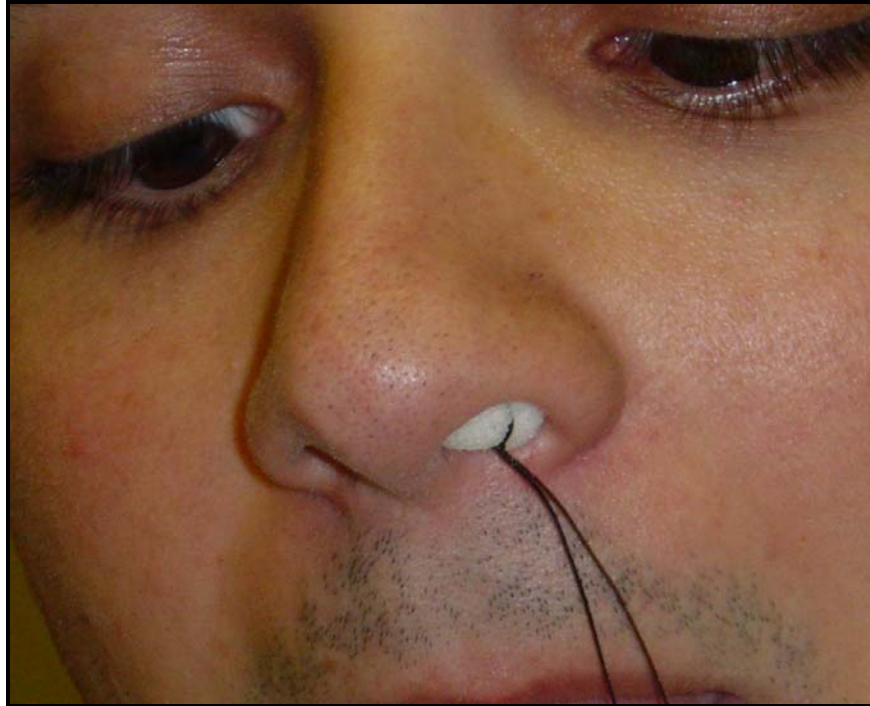
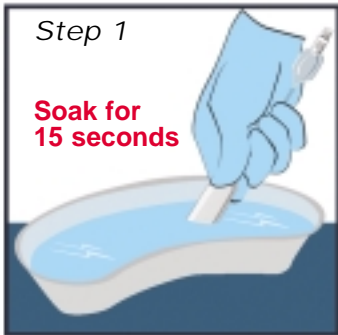Figure 2: **The fully inserted pack:** NB Nil protruding anteriorly



Making Epistaxis a Non-Event!

Steps For Placement

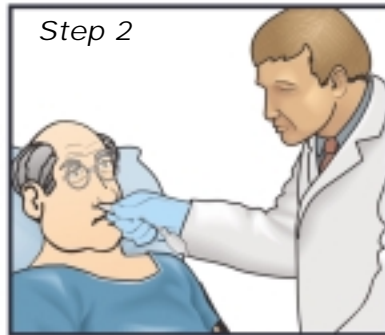


Step 1

Soak for 15 seconds

Soak the Rapid Rhino in sterile water for 15 seconds converting Hydrocolloid fabric to a self-lubricating surface.

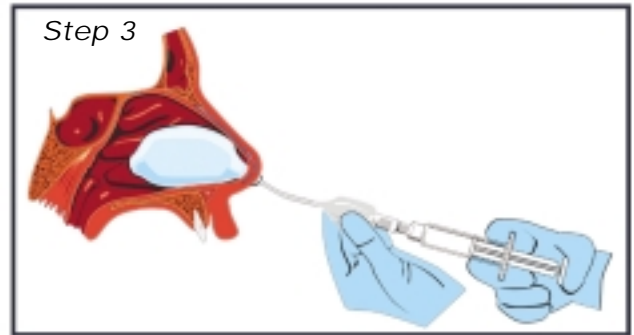
Topical ointments are **not** needed, some antibiotic ointments may **inhibit** hemostatic effectiveness of fabric!



Step 2

Insert and **slide** the Rapid Rhino along septal floor of the nasal cavity.

Be sure fabric ring, (which can be felt at proximal end of the catheter), **IS INSIDE THE NARES**. This allows the cuff to unfold, as seen in Step 3.



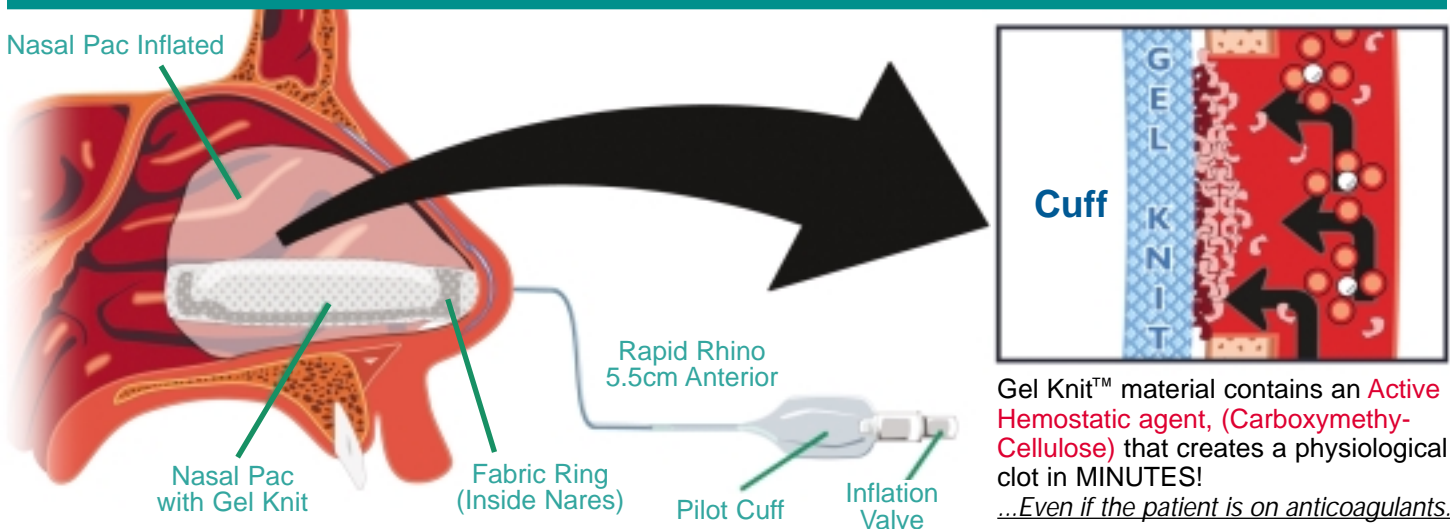
Step 3

Inflate cuff with **AIR Only**. The cuff will conform to the nasal anatomy providing even, gentle Tamponade.

The cuff **delivers** a highly **active hemostatic** agent directly to the wound site. Pilot cuff provides direct tactile pressure feedback. (Similar to placing an ET tube.)

Amount of air is determined by the size of patient's nasal anatomy, the maximum volume of air will result in a **firm Pilot Cuff**.

Hemostasis & Tamponade Working Together!



Gel Knit™ material contains an **Active Hemostatic agent, (Carboxymethyl-Cellulose)** that creates a physiological clot in **MINUTES!**

...Even if the patient is on anticoagulants.



Step 4

Simply tape pilot cuff to side of patients face. Gel Knit fabric will maintain a moist wound healing environment, allowing device to be removed in **24 hours**.

Non Adherent surface will not stick to new clot upon removal, minimizing subsequent re-bleeds.

Control Epistaxis in Minutes!

Items Needed:

- | | |
|-------------------|-----|
| 1. Rapid Rhino | 450 |
| 2. 20cc Syringe | 550 |
| 3. Sterile Gloves | 551 |
| 4. Sterile Water | 750 |
| 5. Emesis Basin | 752 |
| 6. Tape | |

Cat No.

Rapid Rhino Sizes:

- 4.5cm Anterior
- 5.5cm Anterior
- 5.5cm Anterior - Airway
- 7.5cm Anterior/ Posterior
- 7.5cm Ant./Post. Bilateral

Applied Therapeutics, Inc.
3104 Cherry Palm Drive, Suite 220
Tampa, FL 33619
813.623.1400 / Fax: 813.623.3737
Toll Free: 877.682.2777

visit our website at
www.RapidRhino.com
to view animated demo

NASAL FRACTURE

- Check for associated injuries (facial fractures, minor head injury etc)
- Look for deviated bones / cartilage
- If bleeding 1st aid as per Epistaxis advice
- If skin disrupted – close wound + oral ab's (e.g. Augmentin 375mg TDS)
- Exclude septal haematoma:
 - Swelling of the nasal septum occluding airway – usually bilateral
 - Touch with cotton bud to confirm boggy
 - Refer ENT ON CALL – keep fasted

If simple fracture – refer to CEM website for advice on arranging out patient follow up

PERIORBITAL CELLULITIS / MIDFACIAL INFECTION

- Potentially life threatening (via cavernous sinus thrombosis) / threat to vision
- Usually a complication of acute sinus infection

Treatment:

- Nasal swab (middle meatus) for C&S
- Topical decongestant (Otrivine R + L nostril TDS)
- IV access – AMED, CRP, Blood cultures
- IV Abs – (Benzyl-Penicillin 1.2g QDS, Flucloxacillin 1g QDS, Metronidazole 500mg TDS)
- NBM, IVI
- Visual assessment by Ophthalmology on call for:
 - visual acuity
 - diplopia
 - colour vision (red vision lost first)

CONTACT ENT ON CALL - ? CT orbits / sinuses, drainage in theatre

THROAT

TONSILLITIS

- They are sore and miserable – good analgesia is key
- Most of these should be treated in the community
- Diagnosis – Large, inflamed tonsils, grey exudates suggests EBV (check IM screen)

Treatment:

- If able to swallow:
 - Good analgesia (Co-codamol 30/500 + NSAID)
 - Oral Antibiotic (Penicillin V 500mg QDS / Erythromycin if allergic)
 - Home with advice (Rest 1/52, regular analgesia, drink plenty, finish AB's)
- If unable to swallow:
 - Refer ENT at QEUEH
 - IV Access – FBC, IM screen (for EBV), UE, LFT
 - IVI
 - Kardex:
 - IV Benzyl-Penicillin 1.2g QDS +/- Metronidazole 500mg TDS
 - Regular Paracetamol 1g QDS PO/IV, Diclofenac 50mg TDS PO (or 75mg PR)

QUINSY

This is an abscess in the peritonsillar space (i.e. between the tonsil and the pharyngeal muscles)

Diagnosis:

- Trismus +++ (mouth opening restricted)
- Peritonsillar swelling + erythema
- Uvula deviated from midline by swelling

NB Dental abscess also presents with marked trismus so check gums + teeth

Treatment:

- Is there airway compromise?
 - YES >>> d/w ENT ON CALL for fiberoptic examination
 - NO >>> refer ENT at QEUEH
- IV Access – FBC, IM screen (for EBV), UE, LFT + IVI (Don't be stingy if young)
- IV Benzyl-Penicillin 1.2g QDS + Metronidazole 500mg TDS
- Regular Paracetamol 1g QDS PO/IV, Diclofenac 50mg TDS PO (or 75mg PR)

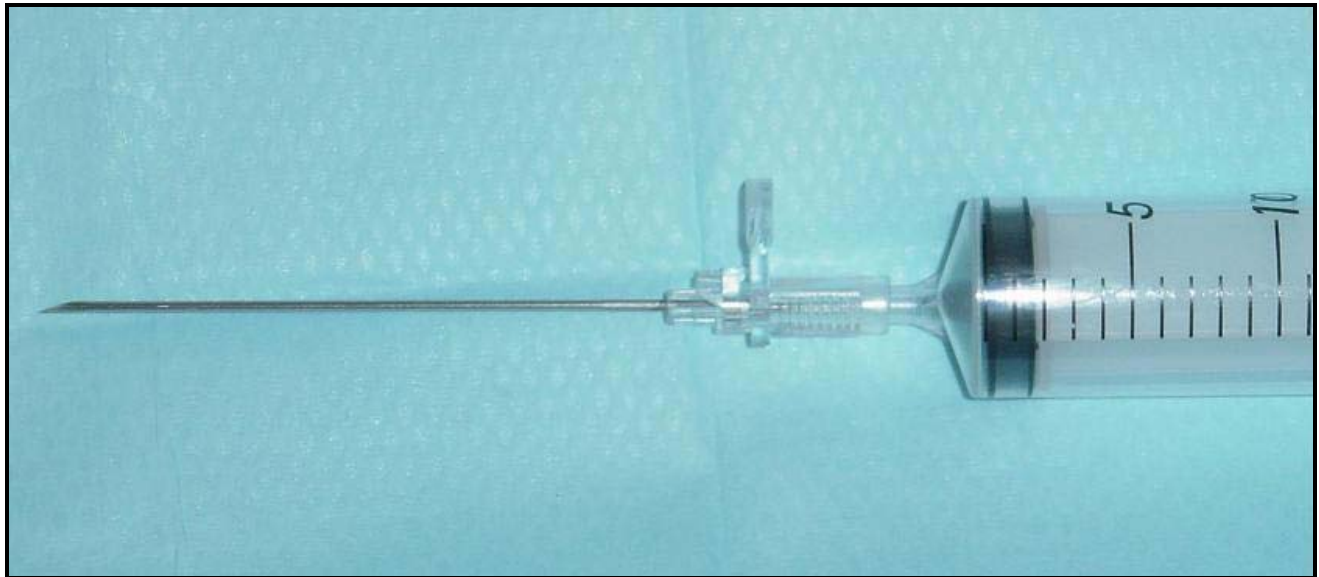
ENT will perform drainage: (See Figure 3 & 4)

- Spray with 4% Lignocaine (get to hold in mouth for as long as possible)
- Using headlight + tongue depressor inspect
- Aspirate using Grey venflon needle & 10ml syringe
- Aim for point of maximal fullness (just lateral to tonsil)
- Do not insert flange of needle beyond upper incisors
- Gargle with water afterwards (bleeding is normal)
- Send Pus for C&S

Figure 3: **View of the Tonsils (Normal):** The X marks the usual site of aspiration in a quinsy

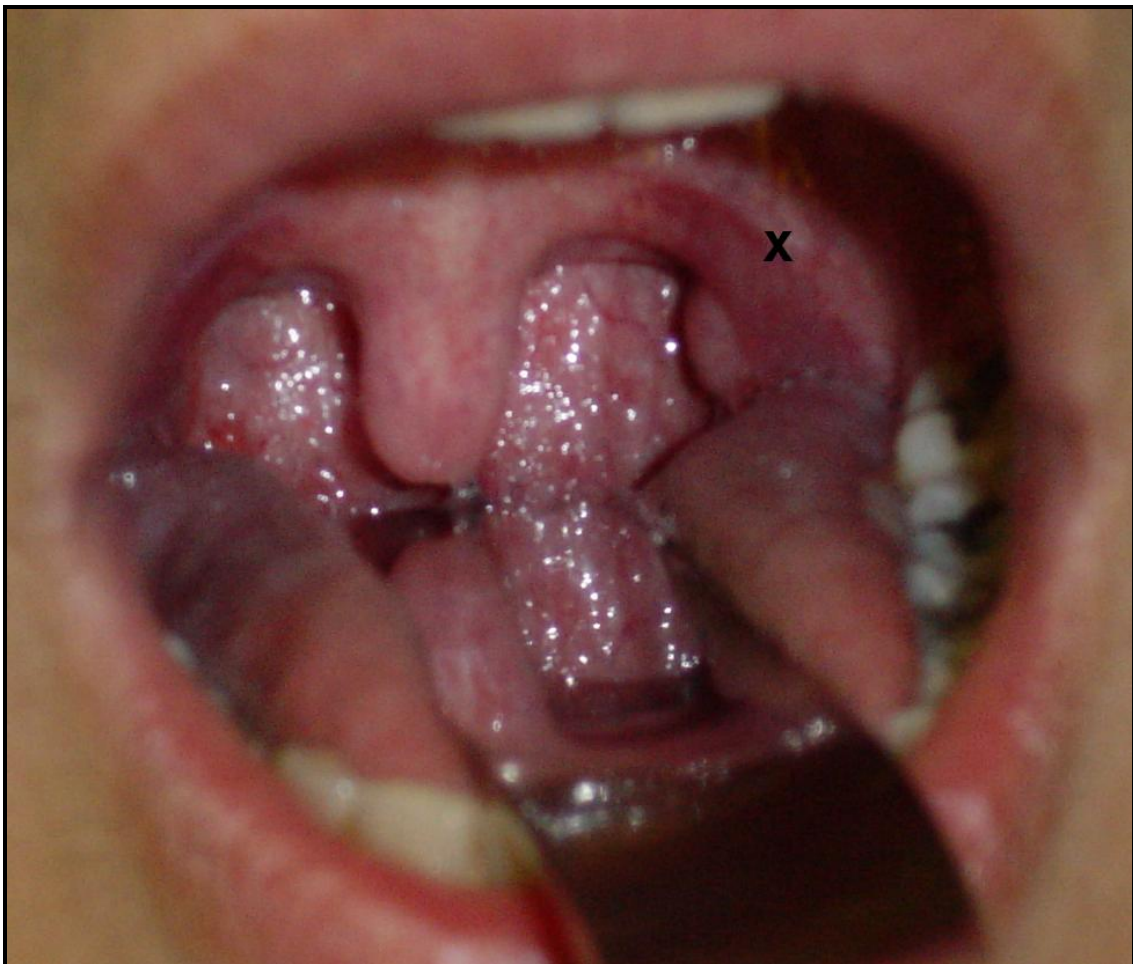

Figure 4: **Grey Venflon needle & Syringe:** Note flange – Do not insert beyond incisors



ACUTE DYSPHAGIA = FOOD BOLUS / FOREIGN BODY OBSTRUCTION:

History:

- Unable to swallow since incident (spitting saliva)
- Meat bolus most common (is there a bone involved?)
- Discomfort at laryngeal level – any lower suggests ?general surgical territory

Investigations:

- Give some sips of water to drink & observe
 - (immediate regurgitation suggests high obstruction)
 - (delayed regurgitation >30 secs suggests low obstruction)
 - (no regurgitation suggests obstruction passed – try with sloppy diet e.g. yoghurt)
- If obstructed:
 - Soft tissue XR neck
 - ? bone
 - gas in upper oesophagus (suggests cricopharyngeal bolus)
 - CXR ? aspiration

Treatment:

- If “soft bolus” – i.e. no bone/dentures/coins etc:
 - Refer ENT at QEUEH:
 - IV access, FBC, U&E
 - IVI, NBM
 - IV / IM Buscopan 20mg, repeat after 30 mins if not cleared, 8 hourly thereafter
 - Kardex
- If “hard bolus” risk of oesophageal perforation if left –
 - treat as above + d/w ENT ON CALL – fiberoptic examination & arrange theatr

TONSILLAR HAEMORRHAGE

- Occurs up to 2/52 post tonsillectomy
- Can be torrential and life threatening
- Contact ENT ON CALL ASAP +/- Anaesthetics

Treatment:

- IV access – FBC, UE, COAG, X-match 2+ units
- IV ab's (e.g. Augmentin 1.2g TDS)
- NBM + IVI
- Look in mouth for site of bleeding
- CONTACT ENT ON CALL – who will may suggest the following prior to transfer
- LA with 4% Lignocaine spray
- Suction clot if still bleeding
- Cotton wool / swab soaked in 1:1000 adrenaline to bleeding point using forceps
- Hold for as long as is tolerated – patient may find it easier to hold it themselves
- Will need theatre if not settling

FISH BONE / ODYNOPHAGIA (PAINFUL SWALLOW)

History:

- Immediate persistent sensation suggestive of fish bone
- Delayed sensation likely to be simple scratch
- Felt in midline / laryngeal level = tongue base
- Lateralised = ipsilateral tonsil
- Type of fish – Haddock is a big offender

Investigation:

- Look in mouth/tongue base/ tonsils
- Remove with forceps if seen after spraying with 4% lignocaine
- Consider soft tissue XR neck if nothing seen on examination (not all fish bones radio-opaque)
- If able to swallow saliva>>> home
 - Refer to ENT at QEUH for follow up
 -

ENT will:

- LA with 4% Lignocaine spray
- Examine with head light + fiberoptic nasendoscope
- Remove bone with forceps if possible
- Arrange theatre if not accessible

- If unable to swallow saliva ? diagnosis d/w ENT ON CALL

NECK STABBING

Contact ENT + Anaesthetics ASAP (Junior + Consultant)

Treatment via ABC:

- High flow O2
- Secure airway – bubbling wound suggests upper airway breach >>> Intubation / tracheostomy
- IV Access – FBC, COAG, UE, X-MATCH 4 units
- IVI – activate major haemorrhage if torrential bleeding
- Apply pressure to bleeding area
- Document any neurological deficit
- CXR + soft tissue neck
- NBM
- IV Antibiotics if contaminated (Augmentin 1.2g TDS)
- Secondary survey for other injuries

Try to find out what done with (Length of blade, cleanliness etc)

Likely to require theatre for exploration

STRIDOR / UPPER AIRWAY OBSTRUCTION

Do not attempt to tackle alone – contact immediately:

- ENT + ANAESTHETICS – JUNIOR + CONSULTANT
- PAEDIATRICS Reg + CONSULTANT IF CHILD

Initial management:

- High flow O₂
- Sit up
- IV access – FBC, UE, COAG, CRP, G&S, BLOOD CULTURES
- Nebulised adrenaline (1ml 1:1000 adrenaline with 4mls Normal saline)
- Consider IV steroids (hydrocortisone 100mg IV) + Antibiotics (e.g. IV Ceftriaxone 2g)
- CXR +/- Soft tissue neck XR
- ECG if cardiopath
- NBM

ENT will visualise upper airway with Nasendoscope to aid Diagnosis.

Likely suspects include:

- Infective – Supraglottitis/Epiglottitis, Ludwig's Angina (Floor of mouth infection)
- Angioedema – Anaphylaxis
- Neoplastic – Laryngeal tumor / Vocal cord palsy
- Traumatic – Laryngeal fracture / haematoma

Treatment is to secure the airway:

- Preferably by Endotracheal intubation
- Tracheostomy will be required if ET not possible
- Then treat underlying cause

NECK ABSCESS

- Swelling over neck – which is often hot, red, painful
- Check for signs of airway compromise e.g. stridor

Treatment:

- IV access – FBC, UE, COAG, BM, G&S, BLOOD CULTURES
- IVI
- NBM
- Contact ENT ON CALL

ENT will:

- Examine upper airway
- Attempt needle aspiration >>> C&S prior to antibiotics (e.g. 1.2g Augmentin TDS IV)
- Arrange imaging prior to Incision & Drainage if possible

EAR

OTITIS MEDIA - Infection of middle ear space

- Bulging red / dull drum + Pain +++
- Many viral and self limiting
- If >1/7 history consider oral antibiotics (e.g. Augmentin 375 mg TDS 7/7)
- Good analgesia is imperative
- d/c back to GP

OTITIS EXTERNA – Infection of the external ear canal indicated by:

- Red narrow / closed ear canal
- Serous discharge + debris in canal
- Complain of ITCH +++

Treatment:

- Swab ear canal if already had treatment – C&S
- Topical drops e.g. gentisone HC (2 drops TDS, 7/7)
- Analgesia – don't be stingy as can be extremely painful
- If very closed or mucky will need wick / microsuction – contact ENT next day to arrange.

NB – Diabetic patients / those with Pericondritis of the Pinna (pinna hot, red, swollen):

- d/w ENT ON CALL:
- Admit Ward 20, Analgesia, IV Ab's (e.g ceftazidime) + topical drops after microsuction

ACUTE PERFORATED TYMPANIC MEMBRANE

2 main causes:

- Traumatic – cotton buds / head injury
 - Blood in ear canal is definitive sign – do not attempt to remove
 - Likely to heal spontaneously – if kept clean & dry
(Use cotton wool + Vaseline ear plugs in shower)
 - Follow up GP 3-4/52 to check healed
 - **NB** – if head injury ? base of skull # - check:
 - Neuro deficit – esp CN VII, vertigo, total unilateral deafness
 - If suspected d/w ENT who will consider High Res temporal bone CT.
- Infective – Acute otitis media:
 - Pressure of pus in middle ear >>> perforation = blood + pus in canal
 - Single infection likely to resolve so no ab's required
 - Repeated infection - oral ab's +/- topical drops (GP to refer to ENT OPD)
 - Likely to heal spontaneously if kept clean & dry (Ear plugs in shower)
 - Follow up GP 3-4/52 to check healed

ACUTE MASTOIDITIS

Needs prompt drainage to prevent intracranial complications.

Signs:

- Pinna is classically projected forward and there is loss of the sulcus behind.
- The mastoid is red & may be fluctuant. TM will be inflamed.
- Tenderness over mastoid is not reliable – post auricular lymphadenopathy is tender.

If suspected:

- IV access – FBC, UE, CRP, BLOOD CULTURES
- NBM, IVI
- Neuro Exam
- d/w ENT ON CALL re CT scan / drainage in theatre

BELL'S PALSY = an idiopathic lower motor neurone CN VII palsy

- LMN palsy is suggested by absence of forehead wrinkles.
- It is usually painless and can follow URTI.
- Need to exclude other causes, so examine:
 - Neurology
 - Ears – Middle ear infection
 - Neck + Parotid gland for masses
 - Look for vesicles on TM / Soft palate = Ramsay Hunt Syndrome
 - Herpes Zoster infection
 - Treat with Acyclovir

Treatment:

- None or Drug – Acyclovir / Prednisolone / both (week course) –
- Follow up in ENT OPD contact daytime team to arrange – needs Audiogram
- Eye protection – due to lack of eye closure consider:
 - Tape eye shut at night
 - Lacrilube/viscotears
 - Patching when outside (protection from grit)
 - Ophthalmology review if painful / red eye

PINNA LACERATIONS:

Cartilage is at risk if exposed – could result in cauliflower ear

Establish mode of injury (human bites – need to consider Hepatitis / HIV exposure)

Treatment:

- Clean wound thoroughly
- Assess for skin loss (closure will be difficult – d/w ENT)
- If simple injury re-oppose edges with steristrips / sutures if confident
 - Discharge with AB's (e.g. Augmentin 375mg TDS)– to return if signs of infection
- If more complex dress with betadine & d/w ENT re review / repair