

# Epididymo orchitis

?Torsion if:  
Acute onset, severe pain  
High riding testicle  
Absent cremasteric reflex

## Risk Factors

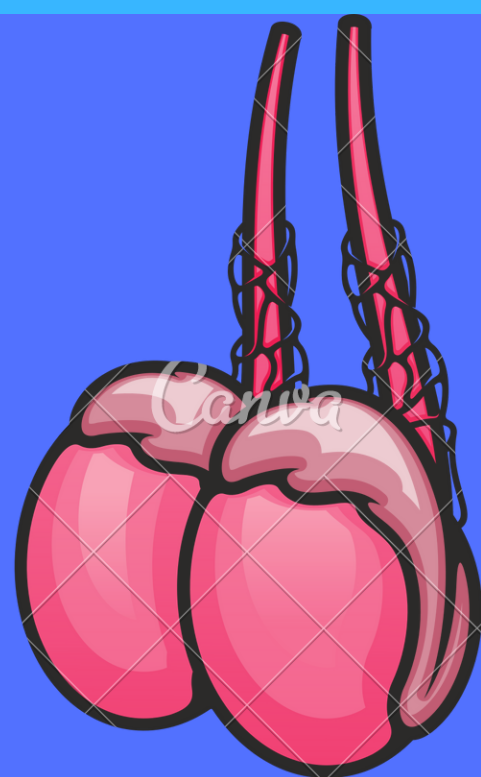
- Unprotected intercourse
- Bladder outflow obstruction
- Recent instrumentation of urethra

## Organisms

- <35 years: Chlamydia/Gonorrhoea
- >35/protected sex: Gram-negative enteric

## Signs & Symptoms

- Unilateral scrotal pain of gradual onset
- Swollen, erythematous, hot testicle
- Pain relieved on elevation of scrotum
- Urethral discharge
- Dysuria



## Investigations

- Exclude testicular torsion
- Urine dip → If positive perform MSSU
- 1st void sample for NAAT
- Urethral swab if discharge

## Management

- If STI is the cause, seek advice from Sandyford RE partner notification
- Gonorrhoea: 1g IM Ceftriaxone
- Chlamydia/Enteric organisms: 200mg Oral Ofloxacin BD for 14 days