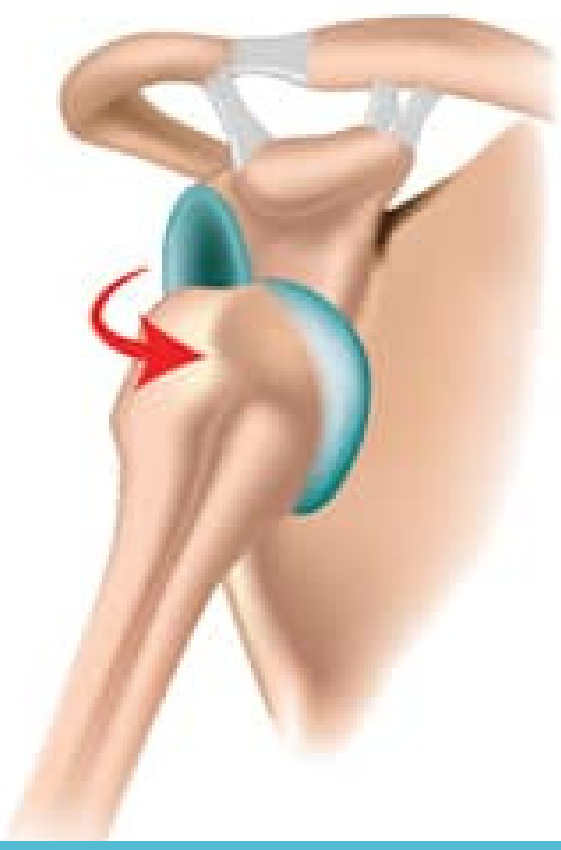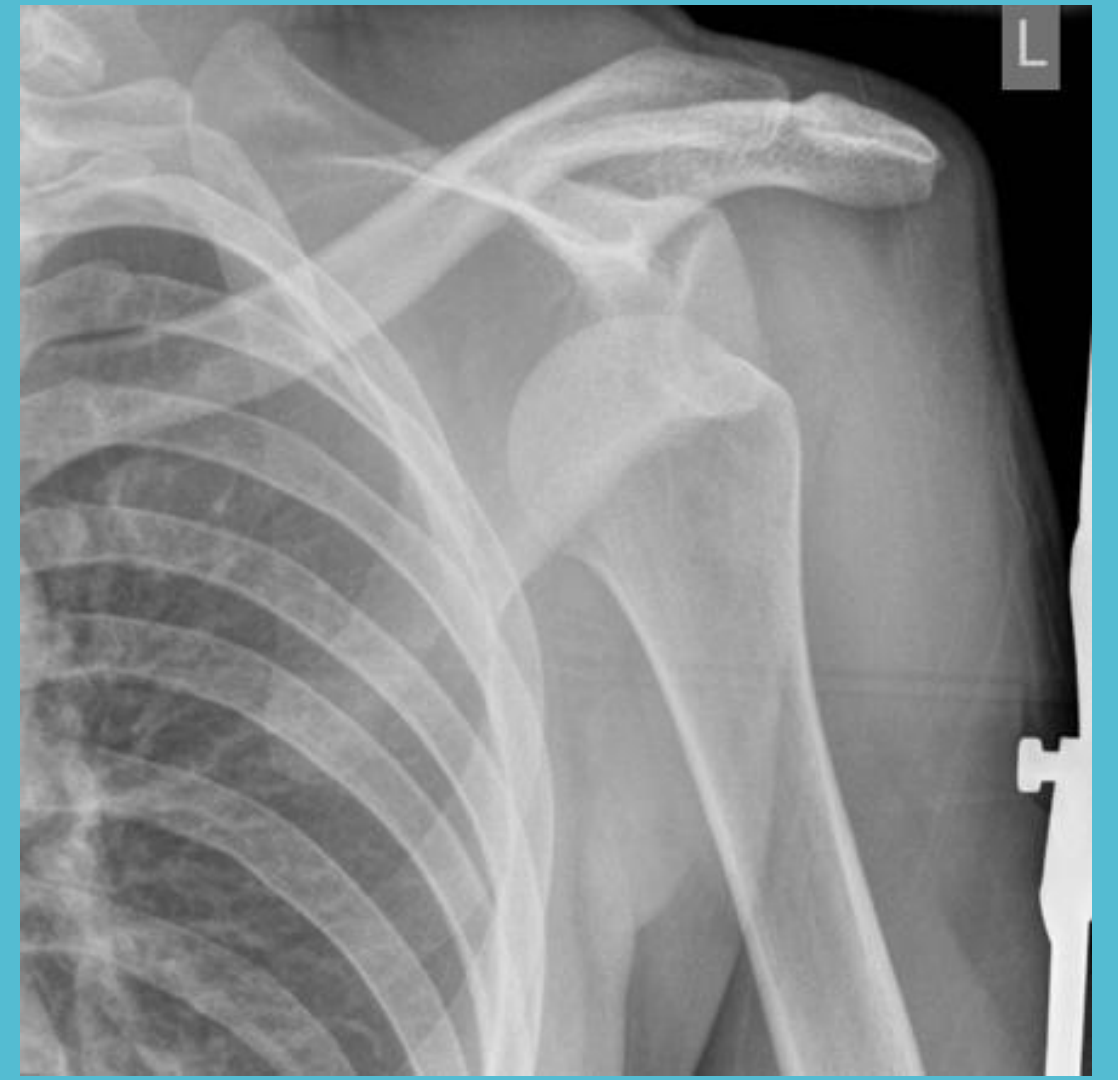




Shoulder dislocation

Reduction

- Numerous reduction methods
- should be performed with local anaesthesia and sedation
- X-ray should be obtained to confirm reduction and ensure that no iatrogenic fractures have occurred during the reduction.
- check neurovascular status of arm.

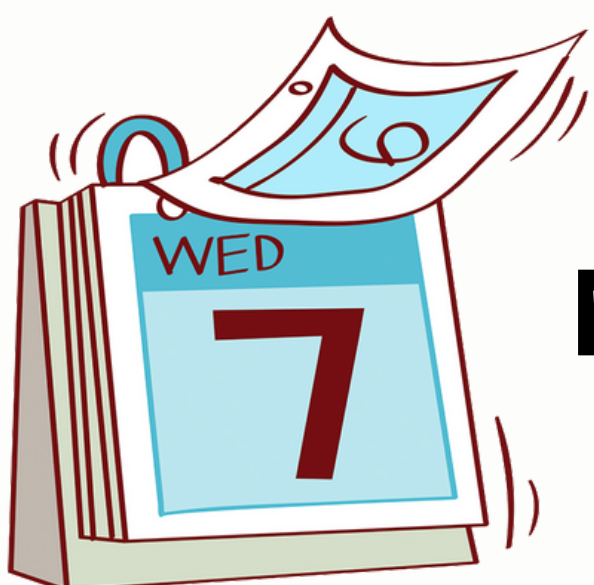

Management- reduction and immobilisation ± surgical referral

First time dislocater:

- <25 years - referral to an orthopaedic surgeon for consideration for stabilisation via Bankart's repair, as this age group is at significant risk for recurrence.
- 25-40 years - conservative Mx
- > 40 years - Perform US to assess cuff. Conservative Mx. If there is a cuff tear, refer to Shoulder # clinic for urgent cuff repair

Recurrent dislocater - should be seen in the shoulder # clinic



No evidence for immobilisation > 1 week