

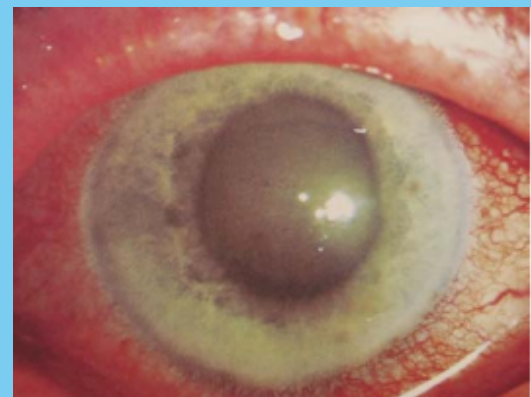
PAINFUL LOSS OF VISION



ACUTE ANGLE CLOSURE GLAUCOMA **EMERGENCY!!!**

Unilateral headache, N&V, blurred vision, Halos around lights
O/E: Fixed and dilated pupil, red eye with hazy cornea, eye feels firm

Tx: IV Analgesia, IV Anti-emetic, IV Acetazolamide + Pilocarpine drops
REFER TO EYES!




Gradual/Insidious onset pain, photophobia, moderate visual disturbance, patients often have suffered previous episodes in the past, Hx of systemic disorder

Tx: Analgesia
Refer to eyes

SCLERITIS

Severe pain- gradual onset, headache, photophobia.
Redness of deep scleral vessels
Proptosis and BLURRED VISION
Poor red reflex
Associated with auto-immune disorders

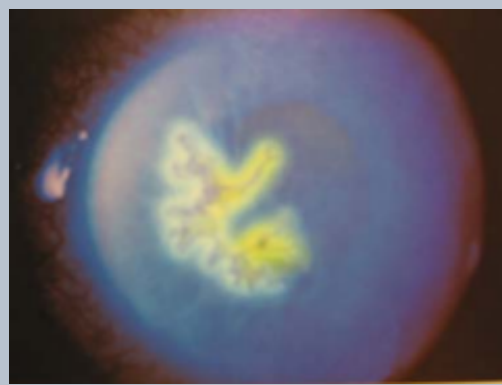
Tx: Analgesia
Refer to eyes



HERPETIC KERATITIS

Red painful eye, photophobia, epiphora, may have blurry vision.
O/E: decreased corneal sensation to light touch. Dendritic corneal ulcer (fluorescein 0.25%)

Tx: Topical Acyclovir



CONJUNCTIVITIS

Mild/Moderate Pain
Discharge- (usually clear)
Unaffected vision
Injection and oedema of conjunctivae

Tx: viral - analgesia
bacterial - Chloramphenicol 1% ointment
allergic - antihistamine

NEVER GIVE STEROID DROPS WITHOUT SPEAKING TO THE OPHTHALMOLOGIST!